

“Un-Ortho-dox”...A New Paradigm in Ortho-Implant Intervention

Aniket Chatterji, Sangita Show, Ritam Kundu, Arka Kanti Dey

Honorary Consultant. Smile D Elite - Multi-speciality Dental Treatment Centre, 52/2A Hazra Road, Kolkata- 700019, West Bengal.

Corresponding Author: Ritam Kundu

ABSTRACT

The success of orthodontic treatment is aimed at achieving a harmonious well aligned occlusion with proper hard and soft tissue balance. Congenitally missing teeth, non-judicial extraction, periodontally compromised teeth are some of the frequent causes of incomplete closure and residual space even after completion of orthodontic therapy which may get complicated with adult age and residual defects in tissue architecture.

In these cases implant placement in 2D or 3D ridge defect can be accomplished through various means like ridge split with expansion, en-block augmentation, sinus lift procedure etc with or without bone graft materials to achieve the optimal platform for implant placement, which are usually performed after completion of the orthodontic therapy. This case report describes a novel technique by utilizing the advantage of remodeling phase of orthodontic treatment by preserving the viability and elasticity of the native bone cell with simultaneous soft tissue remodeling and hard tissue optimization could be achieved successfully without any additional surgical intervention during implant placement in a single adult orthodontic case in both anterior and posterior sites of the lower arch.

Keywords: residual space, congenitally missing tooth, orthodontic remodeling, residual ridge defect, ridge augmentation without conventional bone graft material and membrane, slow drilling protocol without irrigation.

INTRODUCTION

Dental implants have become an integral part of various treatment modalities

for replacement of missing teeth. Since the introduction of root-form endosseous dental implants, the need to establish a proper alveolar ridge has become essential. Availability of adequate amount of bone in terms of vertical as well as horizontal dimension is first requirement for a successful implant therapy. Two-dimensional hard-tissue augmentation techniques are mainly designed for vertically preserved but width-deficient alveolar ridges, and three-dimensional (3D) hard-tissue grafting procedures are intended to gain height and width in volumetrically deficient ridges. Various techniques have been described in the literature to increase the bone volume which includes the autogenous or artificial bone grafting procedures, distraction osteogenesis, alveolar ridge split technique, sinus lift with bone grafts and guided bone regeneration. [1]

Orthodontic forces applied to teeth generate complex mechanical loading patterns comprising compressive, tensile, and shear strains which in turn elicit diverse and complex biological responses in the periodontal tissues immediately surrounding the loaded teeth. [2] This case report presents missing 31, 41 and 46 rehabilitated with implant prosthesis along with simultaneous ridge expansion without any additional surgical procedure.

CASE REPORT

A 24yrs old healthy female patient undergoing orthodontic treatment for past 1.5 yrs was referred to department of

Periodontics of Dr. R. Ahmed dental college & Hospital, for the residual space closure along with balancing the hard & soft tissue harmony in the existing edentulous space

with suitable corrective measures as a part of interdisciplinary treatment protocol. (Fig 1)

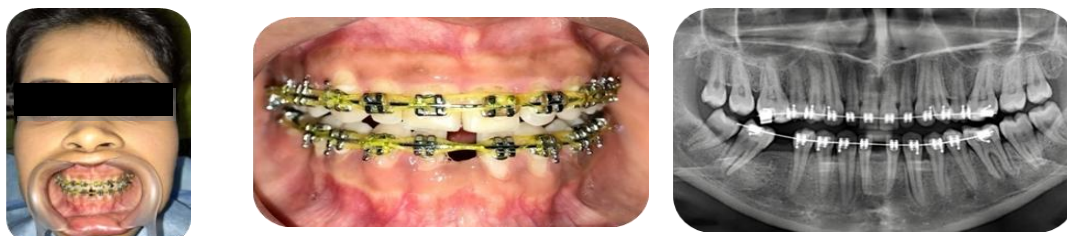

Fig 1: Pre-operative view (clinical photos and OPG) showing missing 31, 41 and 46

As a part of brief history, patient was presented at the verge of completion of the orthodontic treatment with existing residual space in 31,41 (Congenitally missing) and 46 (previously extracted) region. Refurbishment of the missing space with implant prosthesis was planned.

On examination of the 31,41 region lack of mesio-distal as well as facio-lingual width (dimension- 5mm faciolingual, soft tissue level) was evident (two dimensional defect). Similarly gross bone deficiency was evident in the horizontal platform in relation to 46 region (dimension- 5mm faciolingual, soft tissue level). (Fig 2) As per radiological assessment a widened periodontal space suggested that the bone was in active remodelling phase, hence the novel approach was adapted to utilize this phase to maximize the therapeutic outcome keeping the viability of the tissue to the optimal levels.

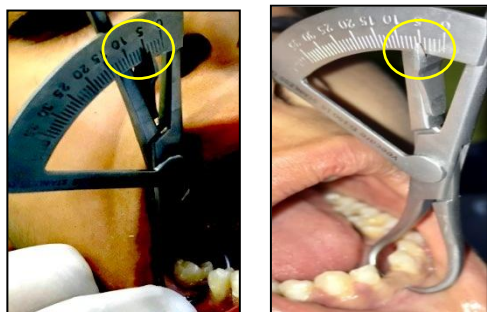


Fig 2: Pre-operative view showing facio-lingual width (dimension-5mm faciolingual, soft tissue level) in relation to 31, 41 and 46.

- The soft tissues appeared to be healthy without overt inflammation.
- Scaling and root planing was done and Oral Hygiene Instructions (OHI) were given.
- After 2 weeks of non-surgical periodontal therapy, surgical counterpart of the implant therapy was planned.
- Entire treatment modality was explained to the patient & an informed consent was obtained from the patient before the surgery.
- Pre-medication (standard regimen) was given.

Surgical Procedure

- a. Intraoral antiseptics was performed by rinsing with 0.2% chlorhexidine digluconate for 30 seconds.
- b. Adequate local anesthesia was achieved with 2% lignocaine hydrochloride (epinephrine-1: 1,00,000) through local infiltration technique.
- c. Prosthetically driven implant placement was planned, Osstem TS III with dimensions (4.5 x 10) mm, bone level implant for replacement of 46 and Dentium NR Line (3.6 x 11) mm bone level tapered implant for replacement of 41 was chosen.
- d. For placement of posterior fixture following steps were performed-

- i. Mid-crestal incision was given in the 46 region and a full-thickness mucoperiosteal flap was raised.

- ii. Gross inadequacy (4mm) of the bone was evident in the buccolingual horizontal platform which was measured with the help of a calliper.
 - iii. Osteotomy was initiated with the help of pilot drill (lindeman drill) till 10mm from the mid point of the bony crest (without performing crestotomy in order to preserve the vertical height).
- Following the "slow drilling protocol technique" [3,4] and utilizing the increased elasticity of the bone to achieve adequate expansion without fracturing the facial cortical bone and keeping the viability optimal.
- i. Sequential osteotomy was performed with specific drills upto the drill with (4.5 x 10)mm , keeping the torque at max (50 Ncm) and speed 20- 80 rpm.
 - ii. This protocol was followed to allow the bone to expand on it's own.
 - iii. The fixture (4.5 x 10) mm with healing abutment (Gingival height/ GH-3mm) was placed. Primary stability of 40 Ncm was achieved with infinity torque control ratchet.
 - iv. Healing abutment stabilized upto 15Ncm.
 - v. Haemostasis was achieved & flap closure was done with non-absorbable 3-0 silk suture.

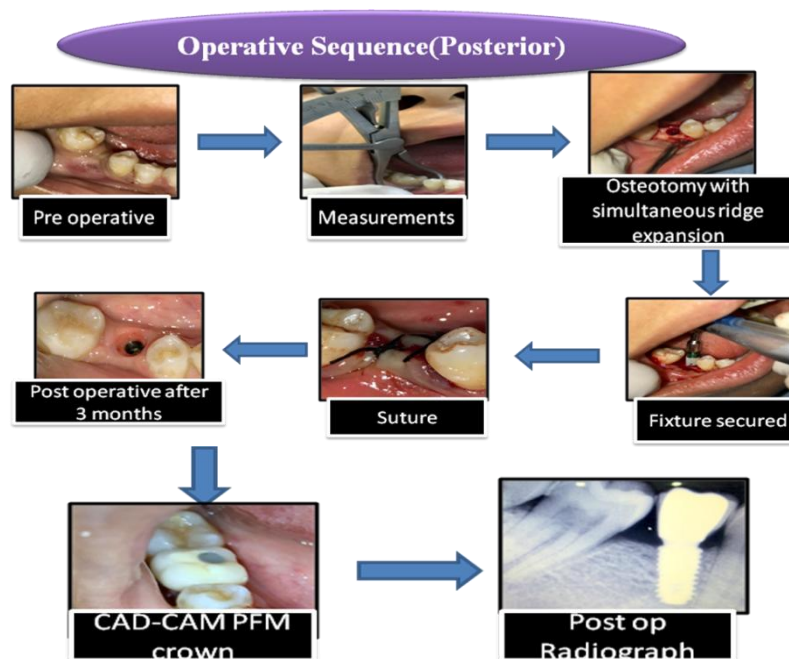


Fig 3: Sequential operative steps in relation to 46.

- e. For placement of anterior fixture following steps were performed-
 - i. Para-crestal incision was given in the 41 region and a full-thickness mucoperiosteal flap was raised.
 - ii. Gross inadequacy (3.5 mm) of the bone was evident in the facio-lingual horizontal platform which was measured with the help of callipers. Horizontal bony platform was tilted lingually.
 - iii. Osteotomy was initiated with the help of pilot drill (lindeman drill) till 11mm from the mid point of the bony crest (without performing crestotomy in order to preserve the vertical height).
 - iv. Following the slow drilling protocol technique and utilizing the increased elasticity of the bone to achieve adequate expansion without fracturing the facial cortical bone.

- v. Sequential osteotomy was performed with specific drills upto the drill with (3.6 x 11) mm , keeping the torque at max (50 Ncm) and speed 20-80 rpm & bone was allowed to expand on it's own.
 - vi. The fixture (3.6 x 11) mm with cover screw was placed. Primary stability 25 Ncm was achieved with infinity torque control ratchet.
 - vii. Cover screw was placed manually.
 - viii. Haemostasis was achieved & flap closure was done with non-absorbable 3-0 silk suture.
- Surgery was conducted along with relevant radiographs during all the necessary steps.

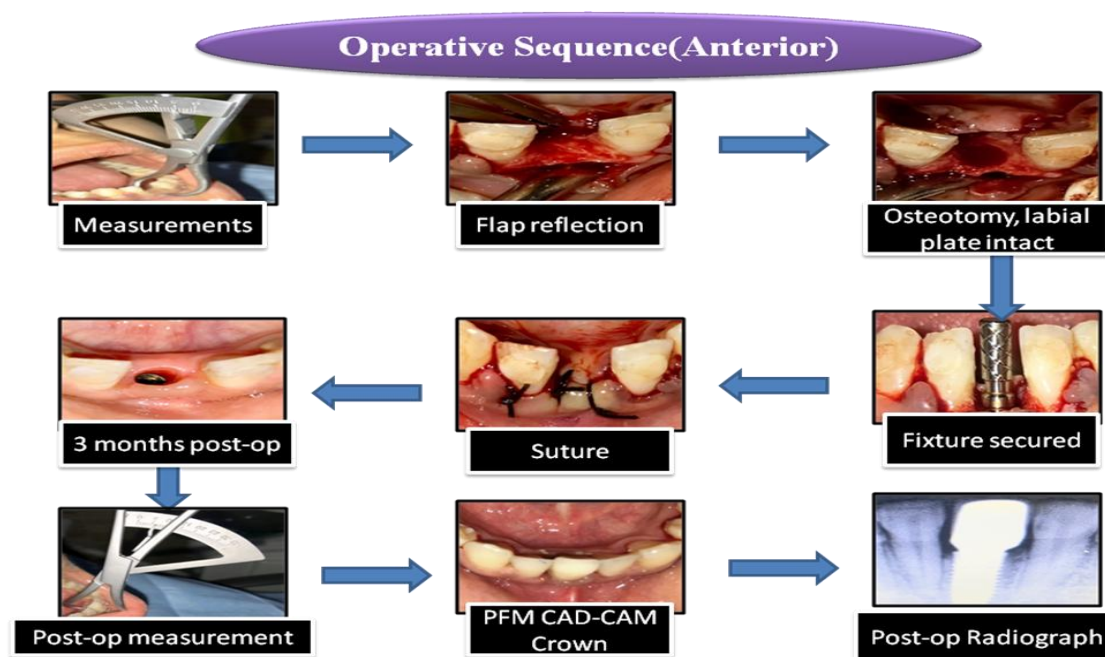


Fig 4: sequential operative steps in relation to 46.

Postoperative Instructions

Postoperative instructions included

- i. Application of ice-packs over the facial skin for 4-5 hrs (applied for 10 minutes, then removed for 20 minutes (1:2 ratio).
- ii. Patient was advised to take antibiotics (Amoxicillin 500mg tds) for 5 days postoperatively.
- iii. Use of a chlorhexidine gluconate 0.2% oral rinse was advised twice daily for 2 weeks post-operatively.
- iv. Lukewarm or cold semifluid diet on the day of procedure, along with easy-to-chew soft food with no sharp edges for 2 weeks was also advised.
- v. Sutures were removed after 2 weeks.

Prosthetic rehabilitation-

- i. Patient was recalled after 3 months for prosthetic evaluation.

- ii. Hard & soft tissue health was assessed both clinically & radiologically.
- iii. Second stage surgery was performed in 41 region and healing abutment (4.3 x 3)mm was placed. Patient was again recalled after 2 weeks for impression making steps.
- iv. Healing abutments were removed from both the regions & soft tissue health was assessed and seemed satisfactory with adequate keratinized gingiva along with proper soft tissue emergence profile with no overt signs of inflammation.
- v. Closed tray transfer coping were placed and impression was made with addition silicon (Affinis, Coltene Whaledent Pvt. Ltd).
- vi. Titanium abutments were milled.

- vii. Crowns were secured with abutment and abutment screws tightened upto 25 Ncm with infinity torque control ratchet. Immediately impressions were transferred to lab without pouring the cast.
- viii. After 7 days lab send the jig trial for exact 3-D simulation of the implant.
- ix. CAD-CAM PFM crown was delivered to the patients after 5 days and crowns were kept 0.5mm infraocclusally.
- x. Access hole was closed in 46 region with resin & in case of 41 region cement retained prosthesis was given with excess cement flushed out.

Prosthetic steps were conducted along with relevant sequential radiographs.

Recall

- Patient was further re-evaluated at 2 weeks and 6 months post-operatively.
- Thereafter, patient was advised to visit in every 6 months for maintenance appointment & was assessed both clinically and radiographically.

RESULT

- On recall examination 2 weeks post-operatively, the surgical site showed complete healing. {Fig. 11}
- The patient was recalled after 3 months and considerable increase in horizontal component was appreciated, 6.5mm from the initial width that is 5mm (including soft tissue component) in anterior region & 8.6mm from 5mm in posterior region.

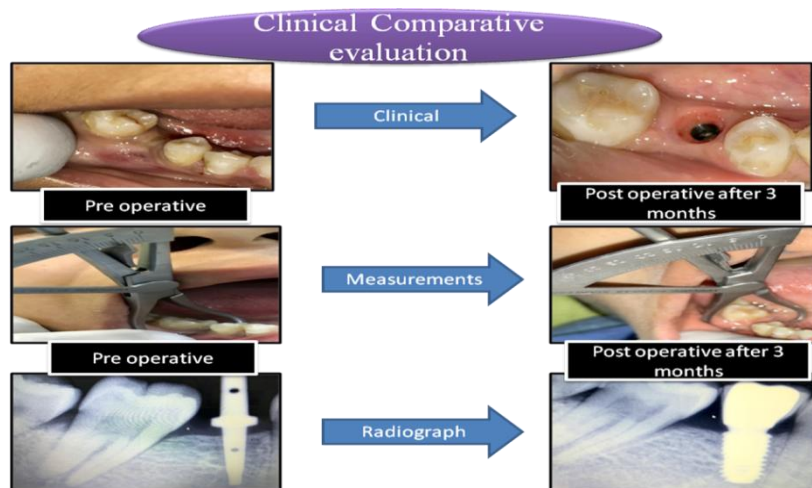


Fig 5: Comparative evaluation pre-operative and post-operative in relation to 46.

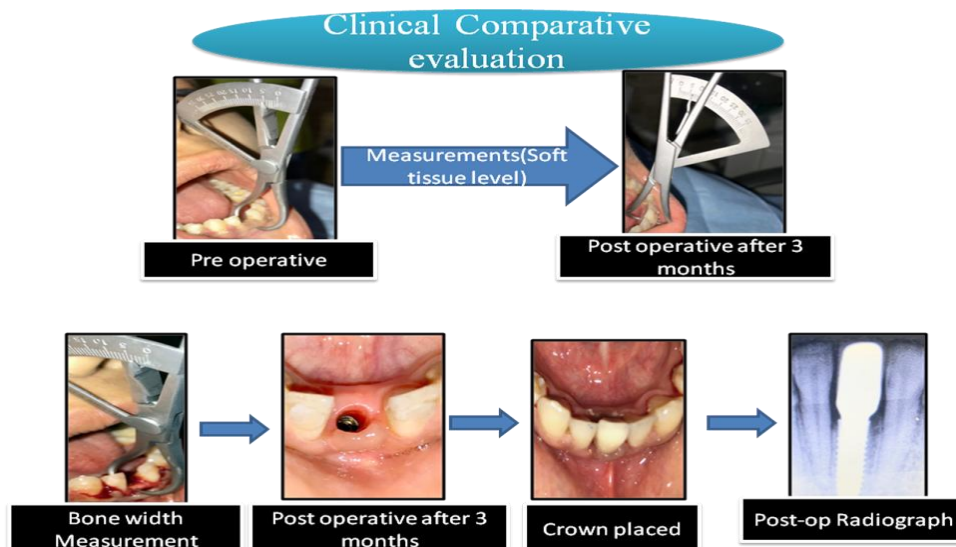


Fig 6: Comparative evaluation pre-operative and post-operative in relation to 31 and 41.

DISCUSSION

Tooth movement induced by orthodontic force application is characterized by remodelling changes in the dental and periodontal tissues. These changes occur by a complex dynamic process known as "mechanotransduction" which enables the application of controlled force in a manner that allows correct and balanced alignment of the occlusion. [4-5] These orthodontic changes are accomplished by two interrelated processes involved in tooth movement namely, deflection or bending of the alveolar bone and remodelling of the periodontal tissues, including the dental pulp, periodontal ligament (PDL), alveolar bone, and gingiva. The applied force causes the compression of the alveolar bone and the PDL on one side, while on the opposite side the PDL is stretched. As a consequence of mechanical loading periodontal tissue vascularity and blood flow are altered, resulting in the local synthesis and release of various molecules such as neurotransmitters, cytokines, growth factors, colony-stimulating factors and arachidonic acid metabolites. The cellular responses are evoked by the released molecules in the various cell types in and around teeth, providing a favourable microenvironment for tissue deposition or resorption. The activation of various cell-signalling pathways ultimately stimulate PDL turnover, as well as localised bone resorption and bone deposition. This biomechanical dynamic phenomenon of orthodontic bone remodeling was judiciously utilized in this case, to rehabilitate the residual space that remained after completion of orthodontic treatment by implant prosthesis. [9]

The slow drilling protocol was carried out at speed of 20-80 rpm without irrigation for the surgical osteotomy and implant site preparation. Eventually the countersinking phase was also carried out at low speeds of 20-80 rpm, without saline irrigation. [4] This protocol enabled the viability of the native bone to be restored to the optimal levels and due to the slow speed

the property of elasticity was exercised during the surgical procedure. Irrigation washes away signaling proteins and other soluble substances that play an active role in bone regeneration. Flood irrigation, either with saline, can drag and dissolve osteoinductive signaling proteins present in the bone extracellular matrix, such as bone morphogenetic proteins, growth factors, and those synthesized in response to the drill insult. [6] The specific physiologic function of these signaling proteins is to transmit activation messages to the local cells so that they can react to the deterioration suffered in the microenvironment. [7-8]

In this instance we have achieved almost all our necessary goals that was intended. But the additional gain that was achieved during the procedure was considerable gain in the width of the ridge (1.5 & 3.5 i.r.t 31,41 region and 46 region respectively) and that was stable even after 6 months post-operatively. The probable reason of this additional gain could be the increased elasticity of the bone due to the ongoing orthodontic procedure and the resultant remodeling phase, which allows additional expansion of the ridge in the horizontal platform without cortical fracture.

CONCLUSION

In this case report it can be concluded that the novel approach of implant prosthesis by slow drilling protocol, utilizing orthodontic remodeling phase judiciously to achieve more viability of the native bone cells resulted in simultaneous expansion of the alveolar ridge at the implant site without undergoing any additional augmentation procedure. This conservative approach not only made the treatment more affordable (no use of additional bone graft materials or costly and technique sensitive instruments and surgical procedures), but also less time consuming thereby making this treatment modality more acceptable to the patients. The outcome of the treatment modality and accomplishment of the increased alveolar

ridge width remained stable 6 months post operatively.

However, studies with a longer study period and larger sample size are required to determine the success rate and the predictability of this procedure.

REFERENCES

1. Mittal Y, Jindal G, Garg S. Bone manipulation procedures in dental implants. *Indian J Dent* 2016;7:86-94.
2. T. P. Garlet, U. Coelho, J. S. Silva, and G. P. Garlet, "Cytokine expression pattern in compression and tension sides of the periodontal ligament during orthodontic tooth movement in humans," *European Journal of Oral Sciences*, vol. 115, no. 5, pp. 355–362, 2007.
3. Eduardo Anitua, Carmen Carda, Isabel Andia, A Novel Drilling Procedure and Subsequent Bone Autograft Preparation: A Technical Note, *Int J Oral Maxillofac Implants* 2007;22:138–145.
4. A. Miyagawa, M. Chiba, H. Hayashi, and K. Igarashi, "Compressive force induces VEGF production in periodontal tissues," *Journal of Dental Research*, vol. 88, no. 8, pp. 752–756, 2009.
5. S. Sprogar, T. Vaupotic, A. Cor, M. Drevenšek, and G. Drevenšek, "The endothelin system mediates bonemodelling in the late stage of orthodontic tooth movement in rats," *Bone*, vol. 43, no. 4, pp. 740–747, 2008.
6. Uchida S, Sakai A, Kudo H, et al. Vascular endothelial growth factor is expressed along with its receptors during the healing process of bone and bone marrow after drill-hole injury in rats. *Bone* 2003;32:491–501.
7. Groeneveld EH, Burger EH. Bone morphogenetic proteins in human bone regeneration. *Eur J Endocrinol* 2000; 142:9–21.
8. Oreffo RO. Growth factors for skeletal reconstruction and fracture repair. *Curr Opin Investig Drugs* 2004;5:419–423.
9. A. Shahrul, Y. Zulham, A. Intan, W. Rohaya and A. Zaidah ; Cellular and Molecular Changes in Orthodontic Tooth Movement; *The Scientific World Journal* (2011) 11, 1788–1803.

How to cite this article: Chatterji A, Show S, Kundu R et.al. "Un-Ortho-dox"...a new paradigm in ortho-implant intervention. *International Journal of Science & Healthcare Research*. 2020; 5(1): 12-18.
